

Fracture of the Zygomatic Arch: Prospective Study of 20 Cases, Epidemiological Evaluation and Treatment

MABIKA BREDEL DJERI DJOR ¹, KHALISSA Lemtouni ², Kabbaj Houda ¹, Garango Allaye ¹,
Aboulouidad Salma ¹, ElBouhi Mohammed ¹, Mansouri Nadia Hattab ¹

¹ Department of Maxillo-facial Surgery, Faculty of Medicine and Pharmacy, Cadi Ayyad University, Mohammed VI University Hospital, Marrakech, Morocco

² Faculty of Medicine of Sfax, University of Sfax, Sfax, Tunisia.

Abstract:

Introduction: Isolated fractures of the zygomatic arch represent a maxillofacial emergency. They are a source of morphological and functional sequelae that are sometimes debilitating but often remain underestimated. Aim: to analyze our diagnostic and therapeutic strategy in fractures of the zygomatic arch.

Material and methods: A cross-sectional and descriptive study with prospective data collection, over a period of six months, from January to June 2017, conducted at the Department of Maxillofacial Surgery, Aesthetics and Stomatology at the Mohammed VI University Hospital in Marrakesh, involving 20 patients who presented an isolated fracture of the zygomatic arch. The distribution of fracture types was based on Yamamoto classification.

Result: The average age of patients was 31.5 years, with a clear male predominance (90%). Road accidents were the main cause (60%), followed by brawls (25%). Orthopedic treatment with Ginestet hook, fixed-field and Gillies technic were initially performed in 14 cases (70%) and surgery in 3 cases (15%). We believe that type 4 and 5 fractures with obvious morpho-functional disorders should require surgery and the other types should be orthopedic and converted to surgery if instability persists. The limitation of mouth opening in 3 patients was most often the result of a lack of reductions rather than muscle contraction.

Keywords: zygomatic arcade, epidemiology, fracture reduction and compression, sequelae

1. INTRODUCTION

The fracture of the zygomatic arch is a traumatic solution of continuity of the lateral structure of the middle third of the face, formed by the zygomatic processes of the temporal bone and the temporal process of the zygomatic bone.

These fractures are interesting for several reasons: frequency, it represents 5 to 10% of the second maxillofacial fracture [1], concerns particularly the young man, and are source of aesthetic and functional sequelae with risk of permanent constriction of jaws if they are neglected [2].

These fractures should not be underestimated and must require the realization of a precise and rigorous clinical and radiological assessments as well as an adequate and early care, which is not always easy.

It is in this perspective; the goal of this study was to analyze our diagnostic and therapeutic strategy in fractures of the zygomatic arch and to draw attention to this entity often wrongly underestimated.

2. MATERIAL AND METHODS

It is a cross-sectional and descriptive study with prospective data collection, over a period of six months, from January to June 2017, conducted in the Department of Maxillofacial Surgery, Aesthetics and Stomatology of the Mohammed VI University Hospital Center in Marrakech.

It was concerning 20 patients who presented an isolated fracture of the zygomatic arch.

A minimum radiographic and clinical follow-up of more than 1 year was required.

All patients underwent a complete clinical examination for functional signs (limitation of ocular motility, limitation of mouth opening, temporal hypoesthesia) and morphology (sagging of the zygomatic arch relief, lateral enlargement, zygomatic ax blow). Blondeau's radiological incidence has been requested for some first-line patients, but often supplemented with a CT scan.

The Yamamoto classification (Fig.1) has been adopted as a reference [3] for the distribution of fracture types:

Type I : No displacement ;

Type II : Displacement with bone contact at all fracture lines ;

Type III : Movement without bone contact to a fracture line;

Type IV : Movement without bone contact with two broken lines;

Type V : Comminution or displacement without bone contact with 3 or more broken lines.

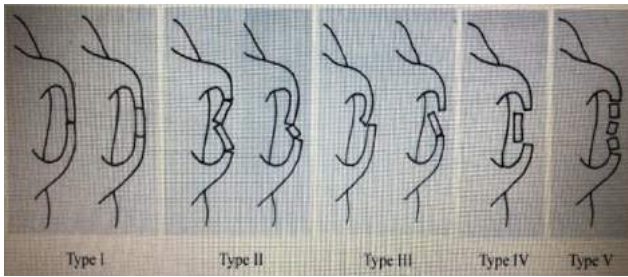


Figure 1 : Classification of the isolated zygomatic arch fracture according to Yamamoto [3].

Management depended on the type of fracture and morpho-functional disorders, ranging from percutaneous reduction to osteosynthesis.

After the therapeutic indication, we divided our sample into three sub groups named G1, G2 and G3 depending on the type of treatment :

- G1: 3 patients who received surgical treatment
- G2: 14 patients who received orthopedic treatment
- G3: 3 patients who have undergone strict supervision

The following parameters were studied for each patient: age, occupation, sex, mechanism of the trauma, consultation time, time of care, limitation of mouth opening, temporal hypoesthesia, morphological disorder, type of fracture, type of treatment, type of reduction, type of restraint, type of sequelae .

3. RESULTS

Among the 201 patients admitted for zygoma fracture, 20 patients had an isolated fracture of the zygomatic arch (9.95%).

The average age of the patients was 31.5 years with a clear predominance of the group between 15 and 30 years, a clear male predominance of the order of 90%. Road accidents were the main cause (60%), followed by brawls (25%) and domestic accidents (15% cases).

The fractures of the zygomatic arch were located on the left side in 12 cases (60%), in 7 cases (35%) they were on the right side, and in 1 case (5%) bilateral.

The consultation time was less than 24 hours for 80% of patients, 5% between 24 and 72 hours and 15% after 72 hours.

The delay in the management was between a few hours after the trauma to 21 days. 15% were treated in emergency care before installation edema, 55% in the first week, and 30% between 8 and 21 days.

The majority of patients presented edema, ecchymosis, limited mouth opening, temporal hypoesthesia, widening of the middle 1/3 of the face, zygomaticax-like appearance (Figure 2), sagging of the arch relief (Table 1).

Table 1: Distribution of symptoms

Clinical Sign	Number of Cases	Percentage (%)
Edema	15	75
Bruise	10	50
Elargement of the 1/3 means of the face	3	15
Zygomaticax-like appearance	8	40
Limitation of mouth opening	11	55
Between 40-30 mm	5	45
< 30 mm	6	54

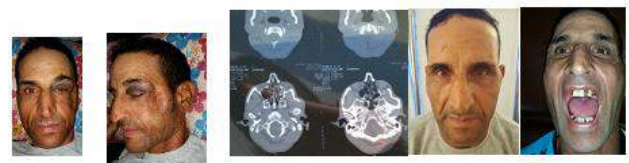


Figure 2: zygomaticax-like appearance face and profile, CT before reduction, photo low view with a good mouth opening in after reduction.

Several types of fractures were found and distributed according to the table 2 :

Table 2: Distribution of lesions according to the Yamamoto classification [3].

Type of fracture	Number of cases (n)	Percentage (%)
Type I	3	15
Type II	10	50
Type III	5	25
Type IV	1	5
Type V	1	5

Medical treatment made of analgesics and corticosteroids has been indicated in all patients.

Orthopedic treatment was performed in 14 cases (70%) (Table 3), and surgical in 3 cases (15%), 3 patients were subject to expectation and surveillance.

The reduction was checked postoperatively by X-rays incidence of Blondeau within 24 hours and found to be satisfactory in all cases.

Table 3: Distribution of orthopedic treatment according to the type of fracture.

Type of fracture	Reduction by Ginesthook	Reduction by fixed clamp fields	Reduction by Gilliestechnic
Type 2	7	2	1
Type 3	1	1	2

No reduction by vestibular route.

On the operating table, 14 orthopedic reductions were stable after at least one attempt. The fracture remained

veryunstable and required conversion to osteosyn thesis for restraint (Table 4).

Table 4: Distribution of fracture stability after orthopedic treatment

Type of fracture	Stable	Unstable
Type 2	10	0
Type 3	4	1

On the 3 patients who underwent surgical treatment, 2 were indicated immediately (1 was type 4 and the other was type 5), and one was type 3 converted to surgery after failure of orthopedic treatment.

The translesional way was the first way in one patient, and the hemi-coronal rin the other 2 patients.

The mini-plates of osteo synthesis were the means of contention in the 2patients while the wire of steel was used with 1patient.

During the post operative check in of our patients we noted secondary displacements for a patient of G3, and 1patients of G2. A case was seen on time and reduced again.

The followings equelae found are reported in Table 5.

Table5 : Distribution of sequelae in the 3 groups

	G1	G2	G3
Limitation of mouth opening	0	2	1
Morphologic Sequelae	0	2	1
Cicatricialalopecia	1	0	0

No neurological disorder was found.

A patient in the G2 group who maintained a tight mouth opening limitation with a morphological disorder following vicious position consolidation was operated for osteotomy at 8 months with a satisfactory result after rehabilitation.

Sequelae by fracture type are listed in Table6.

Table6 : Distribution of different sequelae according to type of lesions

Sequelae	Type1	Type2	Type3	Type4	Type5
Limitation of mouth opening	1	0	2	0	0
Morphologic Sequelae	1	0	2	0	0
Cicatricialalopecia	0	0	0	0	1

4. DISCUSSION

A good clinical and radiological evaluation of the fractures of the zygomatic arch allows to better retain the therapeutic indication and to guarantee a good result. The classification of YAYAMOTO was used because of the details it provides unlike the other classifications [3]. Fractures of the zygomatic bone are

a frequent emergency in maxillofacial surgery [4]. Our frequency of 9.95% is similar to Grenoble University Hospital where fractures of the zygomatic arch (FAZ) represent 5 to 10% of zygoma fractures [5]. At the epidemiological level, the male predominance (90%) and the young age (31.5 years) of the patients are related to the literature [5, 6]. This is explained by the fact that this population is indeed more exposed to risky behavior during sports and car activities, and remains more involved in acts of violence. Unlike women whose lifestyle is less exposed to risk factors [7].

Road accidents (vehicle occupants, pedestrians, cyclists) were the most common cause and accounted for 60% of all etiologies in our study of aggression, which is consistent with Bouguila's work [8]. But for the other European series, roads accidents are generally decreasing, and all efforts made in terms of road safety show the effectiveness of these measures [9]. It therefore seems urgent in our context to insist on the need for a strategy to combat this scourge, based on education and information on road safety, in order to reduce the incidence of these fractures. Clinically, the morphological signs were dominated by the loss of zygomatic arch relief. Functional signs were dominated by the limitation of mouth opening that resulted from both pain reflex and coronoid-malar conflict.

The temporal hypoesthesia found in a patient could be explained by compression or attrition of the zygomatico temporal nerve, must be sought before any therapeutic attitude, because it has a medico-legal interest.

The left predominance of the lesions can be explained by a considerable contribution of the aggressions because the majority of the aggressors are right-handed therefore often attack the left side of the victim [10].

Radiological incidence of Blondeau is the most used X-ray examination for any latero-facial trauma but was supplanted by the computed tomography requested for almost all of our patients. It has the advantage of specifying the number and location of the fracture lines, the movements of the various fragments, highlighting muscle incarceration and the existence of another lesion requiring immediate management. Its availability makes its realization easy in urgency [11].

The Blondeau is not often used in diagnosis. It served us more like for some teams in postoperative control. In fact, standard radiographs remain the reference for post-operative para-clinical examinations [12].

In 2008, in France, the High Authority of Health concluded, in a technological evaluation report entitled "Indications of the radiography of the skull and / or the facial solid mass" on the uselessness of the standard radiographs in the lesions of the middle third of the

face. Computed tomography of the facial fundus is the diagnostic reference examination [11].

The purpose of the treatment is the restoration of the shape and harmony of the face and to restore the mouth opening with the lowest morbidity. The means to achieve this are medical, orthopedic and surgical. The principle of this therapy is based on the tandem reduction-restraint either by engrainment or fixation of the fragments.

Several methods for reducing zygomaticarch fractures have been described [7, 13, 14].

We used three types of reduction, percutaneous Ginesthook (8cas), fixed-field clamp (3cas) and reduction by the way of Gillies (3cas). No endobuccal reduction was used. Techniques using endobuccal approaches would pose a risk of infection but leave no scar while those using oral exo routes are considered more infectious but expose to a scarring ransom and a theoretical risk of injury to the facial nerve [10]. No case was lamented in our series.

Fixed-field clamp reduction, used in 3 patients under local anesthesia in the emergency room with satisfactory results, was described in 1999 by Hwang [15]. First, the zygomaticarch fracture is identified, then the localization of the points of anesthesia. Then, the first jaw of the fixed-field clamp is introduced then the second jaw to maneuver the reduction (Fig3).

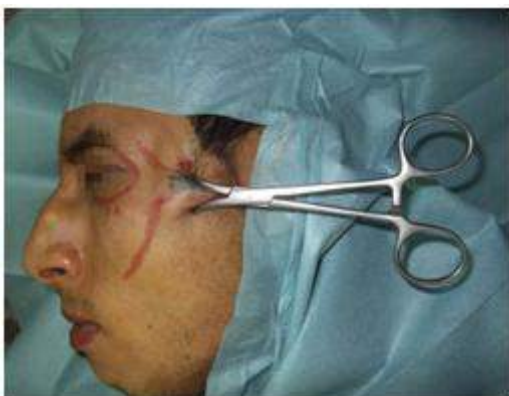

Figure3 : Fracture reduction by fixed clamp field.

This is a simple technique, minimally invasive, effective and especially feasible in emergency room without preconditions. It presents a minimum risk of infection or neurovascular injuries and leaves no scar [10].

Reduction by Ginestet hook was used in 8 patients. It requires control of the force applied during elevation to avoid excessive displacement of the fracture in the opposite direction and compromise any possibility of shattering fragments. Although the crackle that occurs at the time of reduction indicates that the reduction is complete, it must be clinically confirmed. This technique requires experience [16].

The reduction by Gillies technique[13], 3cases of our study makes it possible to carry out safely the reduction of fractures depressions. The incision was drawn in the scalp, next to the temporal fossa, 1 cm in front and 2 cm above the root of the helix. The temporoparietal fascia is opened with the scalpel in the sens of the incision. The reduction of the arch is often enmeshed and stable. This technique presents the risk of a limitation of oral opening by muscular contraction, but not deplored in our study.

For the bloody reduction, 3cases in our series, the coronal way was our main choice (Fig3). It gives a good exposure of the zygomaticarch, facilitating a good anatomical reduction. The risk of neurological damage is lower with minimal morbidity and an aesthetically acceptable scar. It has some disadvantages such as the long duration of operative time, cicatricial alopecia but can be minimized by broken incisions [17].

The fixation of the fracture was achieved by mini plates (2cases), which allowed a fast anatomic and functional reconstruction (Fig4) [18]. As for the use of the fixation by steel wire, it keeps a place in comminutive fractures, 1cases of ourseries.

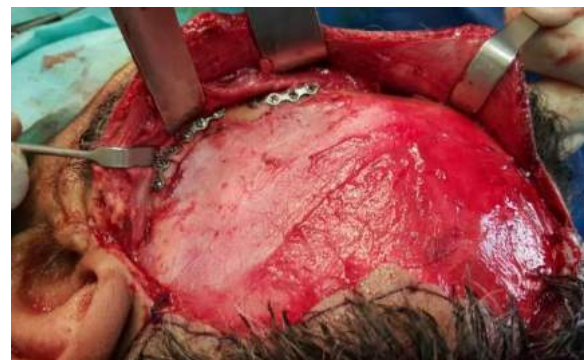

Figure4 : Coronal typ4 fracture exposure and mini plate contention.

However, the management of these fractures remains debated. Schools that opt for conservative treatment [19], which is closed reduction (Gillies technique, for example), consider that the relatively simple clinical results achieved by this technique are satisfactory, and that the inconveniences caused by the open way are dashed. For the opposite side, he believes that post-reduction sequelae are frequent and difficult to manage ; therefore, type4 and 5 fractures should be directly addressed and fixed [20].

For us, the most practical therapeutic approach would be to deal with morpho-functional disorders and the type of fracture. We believe that type 4 and 5 fractures with marked morpho-functional disorders should require surgery and the other types should be orthopedic and converted to surgery if instability persists.

Not displaced fractures of the zygomatic arch (G3) don't require orthopedic or surgical correction. Insofar as these fractures do not lead to aesthetic and functional implications, a simple clinical monitoring is recommended.

In our study, the sequelae were essentially the limitation of oral opening (3 cases) which was most often the result of a lack of reduction rather than muscle contraction, morphological disorders following an insufficiency of reduction and / or secondary displacement.

The management of these sequelae remains a major challenge. It can be avoided if most of the principles applicable to the management of the initial trauma as well as the period of care are respected [21].

5. CONCLUSION

Fractures of the zygomatic arch are becoming more frequent and bring into play the functional and aesthetic prognosis of patients. They are often underestimated. Therefore, they must require adequate and rapid treatment to correct the aesthetic damage and avoid morpho-functional sequelae so the patient can quickly return to an acceptable socioprofessional life.

REFERENCES

- [1] Lebeau J, Kanku V, Duroure F, Morand B, Sadek H, Raphaël B. Traumatismes faciaux au CHU de Grenoble : étude épidémiologique de 961 dossiers sur une période de 365 jours. *Rev Stomatol Chir Maxillofac* 2006 ; 107:23-9.
- [2] GIRAUD O, DUHAMEL P, SEIGNEURIC JB, CANTALOUBE D. Traumatologie maxillo-faciale : modalités thérapeutiques. *Encycl Méd. Chir (Editions Scientifiques et Médicales Elsevier SAS, Paris), Stomatologie*, 22-068-A-10, 2002 ; 14.
- [3] Yamamoto K., et al : Clinical analysis of isolated zygomatic arch fractures. *J Oral Maxillofac Surg* 2007 ; 65 : pp. 457-461
- [4] Carter TG, Bagheri S, Dierks EJ. Towel clip reduction of the depressed zygomatic arch fracture. *J Oral Maxillofac Surg* 2005 ; 63:1244-6.
- [5] Lebeau J, Kanku V., Duroure F., Morand B., Sadek H., and Raphaël B.: Traumatismes faciaux au CHU de Grenoble : étude épidémiologique de 961 dossiers sur une période de 365 . *Rev Stomatol Chir Maxillofac* 2006 ; 107 : pp. 23-29
- [6] Yoshiaki Sakamoto*, Hisao Ogata, Hirokazu Shido, Kazuo Kishi Department of Plastic and Reconstructive Surgery, Keio University School of Medicine, 35 Shinanomachi, Shinjuku-ward, Tokyo 160-8582, Japan
- [7] Zingg M, Laedrach K, Chen J, Chowdhury K, Vuillemin T, Sutter F, et al. Classification and treatment of zygomatic fractures: a review of 1025 cases. *J Oral Maxillofac Surg* 1992 ; 50:778-90.
- [8] J. Bouguila, I. Zairi, R.H. Khonsari, M. Hellali, I. Mehri, A. Landolsi, K. Zitouni. Les fractures de l'os zygomatique : à propos de 356 cas. *Annales de chirurgie plastique et esthétique* 53(6) :495-503 .
- [9] Voss R. The aetiology of jaw fractures in Norwegian patients. *J Maxillofac Surg* 1982 ; 10:146-8. Roberts AH, Carroll MJ, Lamb RL. Windscreens injuries and seat belts. *Lancet* 1983 ; 2:340-1.
- [10] S. Lahmiti, Z. Aziz, M. Lakouichmi, A. Hiroual, A. Bouaichi, N. Mansouri Hattab. Réduction des fractures de l'arcade zygomatique par pince fixe-champ. *Rev Stomatol Chir Maxillofac Chir Orale* 2015 ; 116:92-94.
- [11] Rapport de la Haute Autorité de Santé. "Indications de la radiographie du crâne et/ou du massif facial". 2008. (https://www.hassante.fr/portail/upload/docs/application/pdf/200806/rapport_radiographie_crane_2008-06-30_11-52-59_159.pdf)
- [12] J. Lebeau, V. Kanku, F. Duroure, B. Morand, B. Raphaël. Traumatismes faciaux au CHU de Grenoble: Étude épidémiologique de 961 dossiers sur une période de 365 jours. *Revue de Stomatologie et de Chirurgie Maxillo-faciale*, volume 107, Issue 1, January 2006, Pages 23-29
- [13] Thangavelu K, Ganesh NS, Kumar JA, Sabitha S, Nikil. Evaluation of the lateral orbital approach in management of zygomatic bone fractures. *J Nat Sci Biol Med* 2013 ; 4:117-21.
- [14] Giudice A, Colangeli W, Cristofaro MG. Percutaneous reduction of an isolated zygomatic fracture using a wire suture. *Br J Oral Maxillofac Surg* 2013 ; 51:201-2.
- [15] Hwang K, Lee SI. Reduction of zygomatic arch fracture using a towel clip. *J Craniofac Surg* 1999 ; 10:439-41.
- [16] Kaastad E, Freng A. Zygomatico-maxillary fractures. Late results after traction-hook reduction. *J Craniofac Surg*. 1989 Jul ; 17(5) : 210-4.
- [17] Zhang QB, Dong YJ, Li ZB, Zhao JH. Coronal incision for treating zygomatic complex fractures. *J Craniofac Surg*. 2006 Apr ; 34(3):182-5.
- [18] Kovács AF, Ghahremani M. Minimization of zygomatic complex fracture treatment. *Int J Oral Maxillofac Surg*. 2001 Oct ; 30(5) :380-3.
- [19] Carr RM, Mathog RH. Early and delayed repair of orbito-zygomatic complex fractures. *J Oral Maxillofac Surg*. 1997 Mar ; 55(3) :253-8.
- [20] O'hara De, DelVecchio Da, Bartlett SP, Whitaker LA. The role of microfixation in malar fractures : a quantitative biophysical study. *Plast Reconstr Surg* 1996 Feb ; 97(2) :345-50.

[21] Becelli R, Carboni a, Cerulli G, Perugini m, Iannetti G. Delayed and inadequately treated malar fractures: evolution in the treatment, presentation

of 77 cases, and review of the literature. *aesthetic Plast Surg* 2002 mar-apr ; 26(2) :134-8.