

## Management of Two Rare Case Presentations of Retroperitoneal Cystic Masses Due To Duplicated Ureter (Complete and Uncomplete) and Review of the Literature

Dr. Yasin Idweini PhD MD, FEBU

Chairman of Urology, Urology department Al-Bashir Teaching Hospital Amman –Jordan

### Abstract:

We present our first case of retroperitoneal midline huge cystic mass, as a consequence of multiple congenital abnormalities in the urinary tract; i.e. ectopic ureter, complete duplication of ureter, blind ending ureter, congenital ureteric diverticula's, and abortive renal tissue.

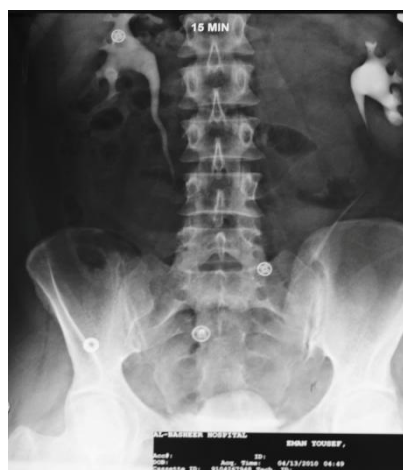### 1. INTRODUCTION

After reviewing the literature on the subject, we can say that the ectopic **ureter is meant, herein**, to imply a ureter whose orifice terminates almost in the bladder neck **and may extend** to the urethra or outside of the urinary tract into one of the mesonephric duct structures.

**As for** male individual; (posterior urethra, seminal vesicles, ejaculatory duct and vas deferens). **Whilst in terms of female individual**, the urethra and vestibule are the most common sites, then vagina, cervix, uterus, Gartner,s duct, urethral diverticulum.

### 2. CASE PRESENTATION

A 35-year old female patient presented with recurrent Lt Loin pain. Her serum creatinine and blood chemistry tests were normal. Urine analysis within normal range. Her IVU showed mild Lt Pelvi-Calyceal system dilatation with shifting of Lt Ureter laterally due to retroperitoneal mass.(Fig.1)



Her abdominal pelvic CT scan showed large elongated cystic lesion in Lt Parapielic region.(Fig.2)

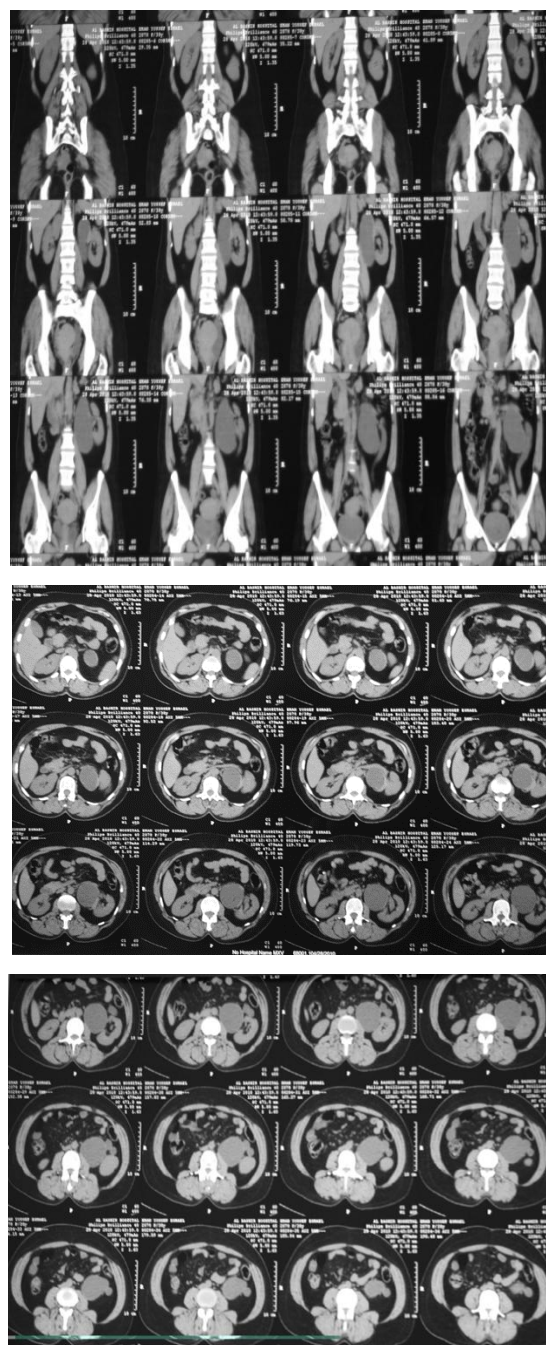
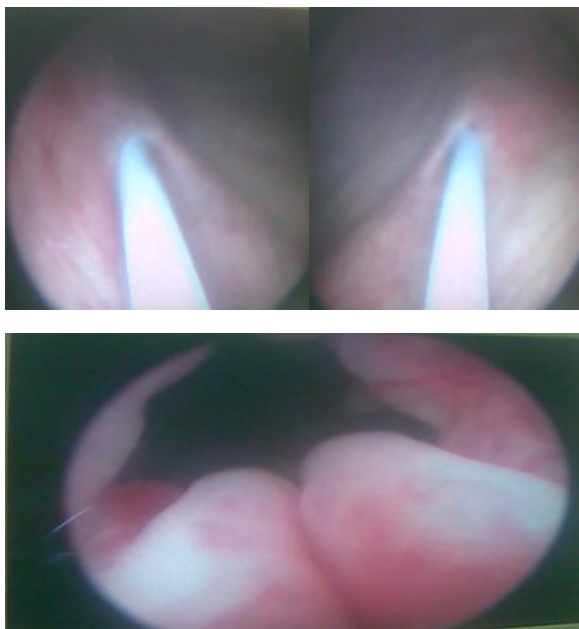

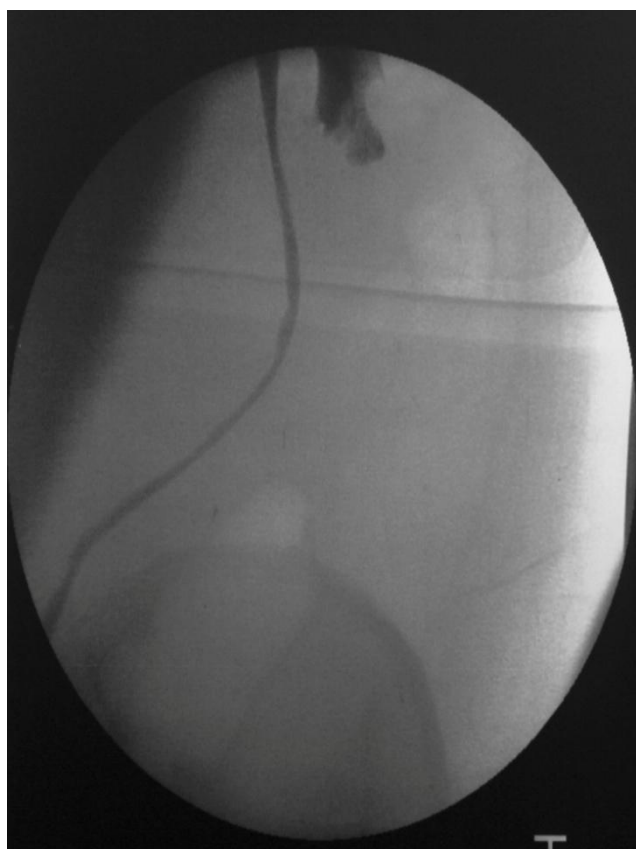Fig 2.

Cystoscopy done for her and showed normal urinary bladder with normal position and shape of both ureteric orifices.(Fig.3)



**Fig.(3)**

Retrograde Lt Pyelography revealed deviation of Lt Ureter laterally. (Fig.4)



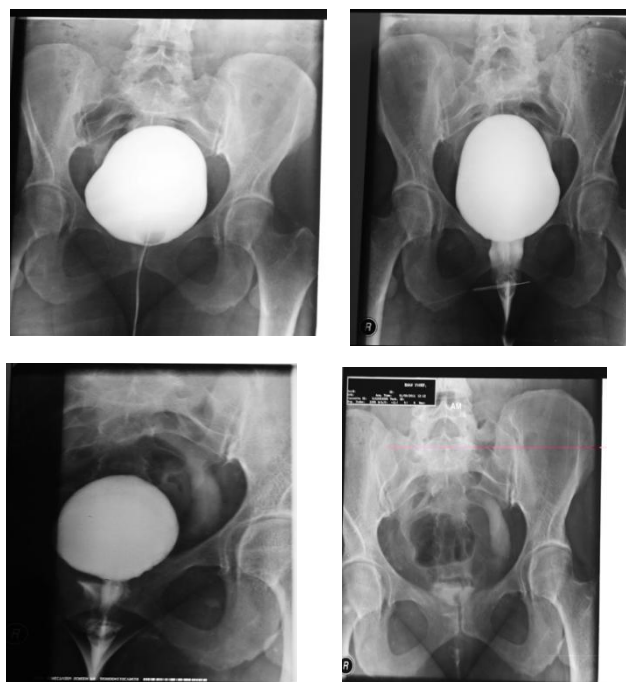
**Fig.(4)**

Exploratory lumbotomy of the Lt kidney performed which was normal with normal ureter but shifted laterally by retroperitoneal huge mass with settlement on the Lt renal pedicle. Excision of the mass performed and it was huge cyst with watery content adherent to the renal pedicle and I left part of thickened cystic wall adherent to the pedicle to prevent any pedicle injury. Her immediate postoperative period was uneventful

Pathology first report **displayed**:Cyst measured 9x9x8cm with fibrous thickened wall infiltrated by acute and chronic inflammatory cells with scattered smooth muscle(pseudo cyst suggesting cystic lymphangioma).

Second report states :The previously described cyst is attached to a stump of a tube like structure measure 1 cm, the cyst is focally lined as Epithelium which is in continuity of the tube like structure attached to it and proved to be urothelium; features are compatible with ureteric cyst without renal parenchyma.(Abortive ureteral duplication and congenital ureteral diverticulum's are very uncommon and have been reported as arising from the distal ureter and could become very large and secondary hydronephrosis can ensue Gray and Skanadlakis 1972)

Her postoperative MCUG and CT scan, after the excision of the retroperitoneal cystic mass showed refluxing ectopic vaginal ureteric orifice in the remained distal segment ureter during micturition phase (Fig.5 Fig7).



**Fig (5).**

and her postoperative IVU showed normal urogram Fig.(6).

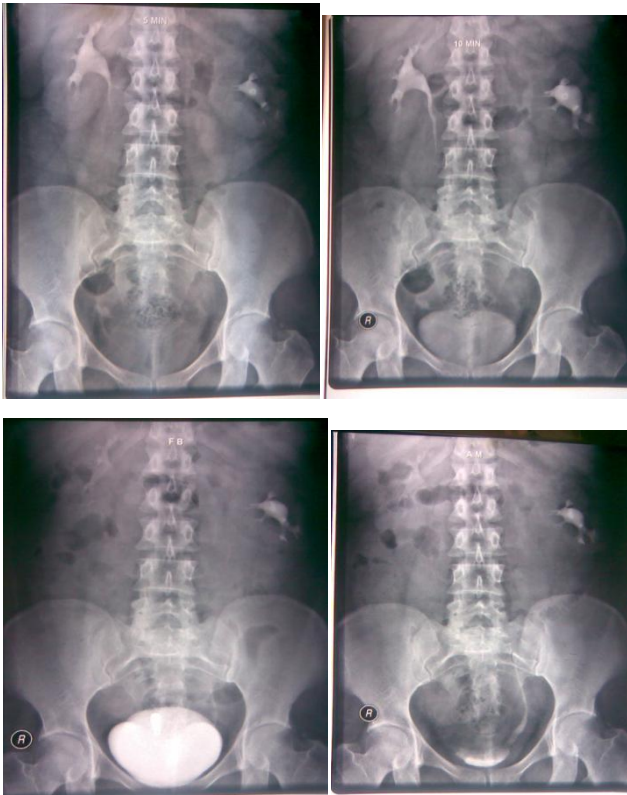


Fig.(6)

Her CT scan after excision of the retroperitoneal cystic mass, revealed normal exploration Fig.(7)

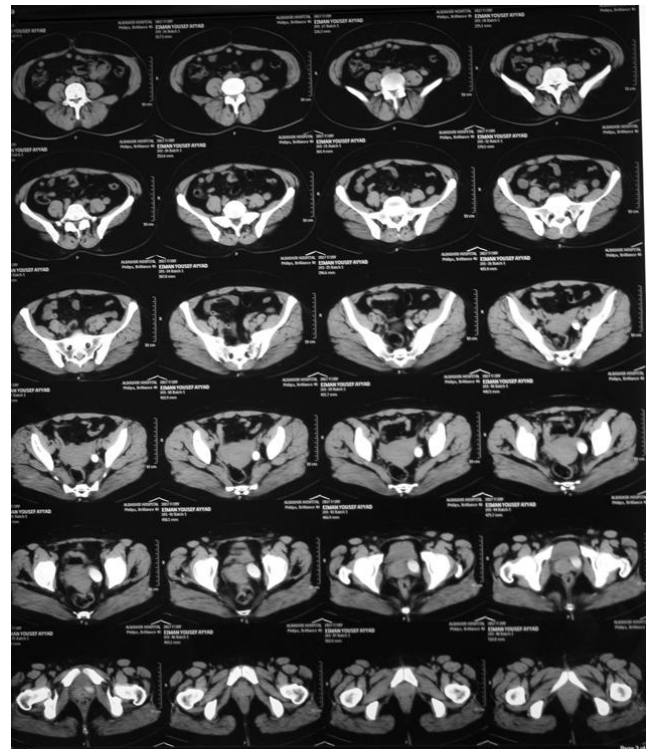
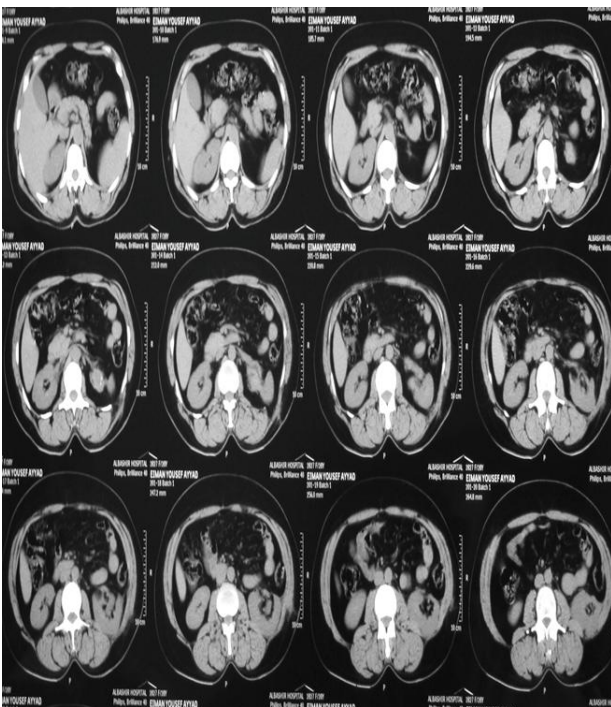


Fig.(7)

### 3. DISCUSSION AND CONCLUSION

Embryologically at 4 weeks gestation, an out pouching arises from the distal mesonephric duct. This out pouching is the ureteric bud, and it interacts with a mass of mesenchyma that is the metanephric blastema.

This interaction results in the ureteric buds are found to be branching and developing into calyces, renal pelvis and ureter. The metanephric blastema is induced to form all elements of the nephron.

Experimental models have shown that, if these interactions are altered or disrupted the blastema fails to change into normal nephrons (1,3).

After its emergence from the mesonephric duct, the ureteric bud may become a split or bifid structure. If two separate ureteric buds originate from the mesonephric duct, then two complete and separate interactions will develop between the ureter and the metanephric blastema. The generated result is represented by two separate renal units and collecting systems from one side, ureters and ureteral orifices from other side.

Congenital diverticula of the ureter is very uncommon and has been reported to arise from the distal ureter above the ureterovesical, mid ureter and ureteropelvic junction (2,4). These diverticula grow to become very

large and secondary hydronephrosis can ensue. The patient may present with abdominal and loin pain (As the presented case) renal colic or a palpable cystic mass.

Most blind-ending ureteral duplications involve one limb of a bifid system. The most unusual case is one involving complete duplication (5). It is postulated that the affected ureteric bud is abortive and fails to contact the metanephros.

Controversy exists in the literature about the distinction between some diverticula and blind-ending duplication. In some cases, it may simply be a matter of terminology; a congenital diverticulum in comparison that has a ballooned appearance. Histologically; both are similar and arising from disordered ureteric budding.

Multiple congenital abnormality of the ureter causing retroperitoneal cystic mass is a rare case, when ectopic, blind duplicated ureter, congenital diverticula and aborted renal tissue exist together. Pre-operative evaluation with radiological exploration is recommended to be useful in confirming the diagnosis in addition to pathologic study to confirm and complete the previous diagnosis.

## 4. SECOND CASE

### Abstract

This case is a case of severe hydronephrosis in the lower kidney moiety in bifid system due to pelvi-ureteral junction stenosis.

Introduction: Hydronephrosis of the lower pole segment is not infrequent and is generally associated with severe reflux into that unit. However, primary ureteropelvic junction obstruction can involve the lower pelvis. (6,7).

We present this case due to its modality of treatment which **was doubled** dismembered pyeloplasty in both moieties (Andersen Hynes technique), **and generated** good outcome.

### Case Presentation:

A 30-year old female patient presented with Lt Loin pain, recurrent UTI. Her serum creatinine and blood chemistry were within normal value.

**Diagnosis:** Her IVU showed upper pole of Lt Kidney opacified by contrast but rest of the kidney appear sac like filled in delayed imagen Fig. (8). By US Lt kidney

appear sac like dilatation measure 7.8x 7.5cm seen in lower pole of Lt kidney, picture represent duplex e obstructed lower pole of Lt kidney

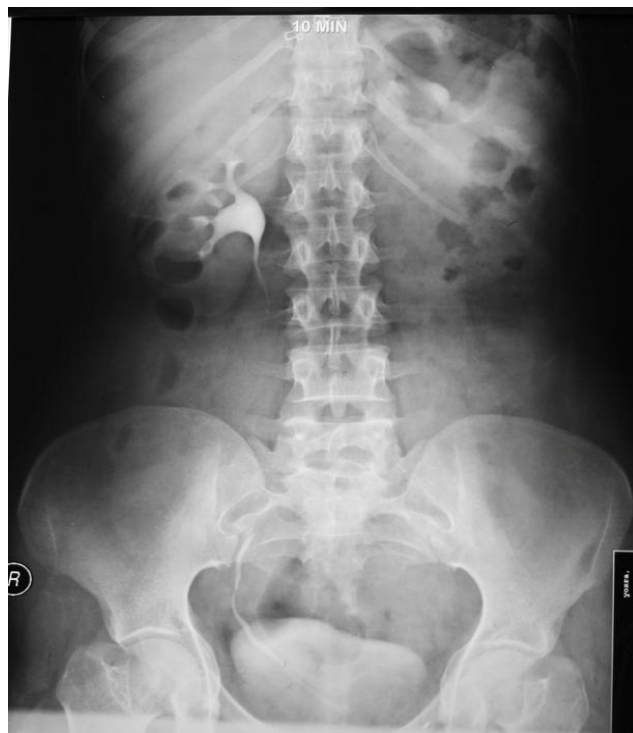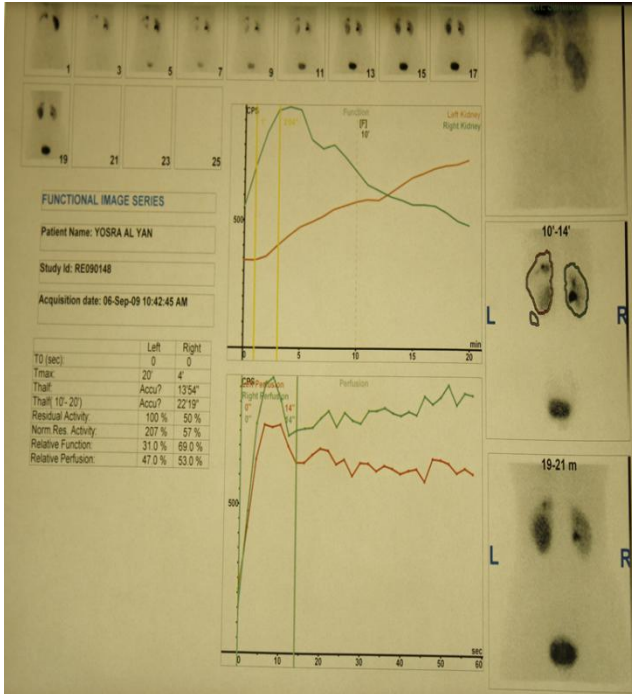


Fig.(8)-a

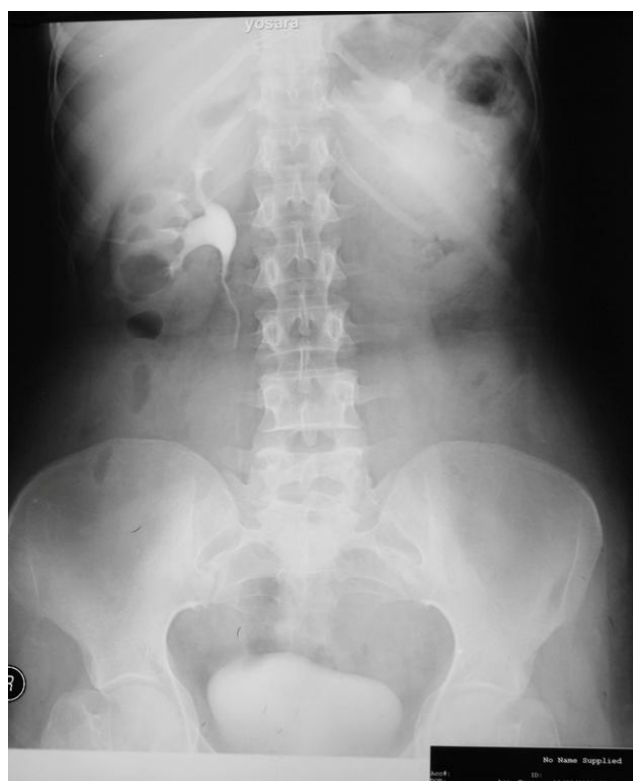

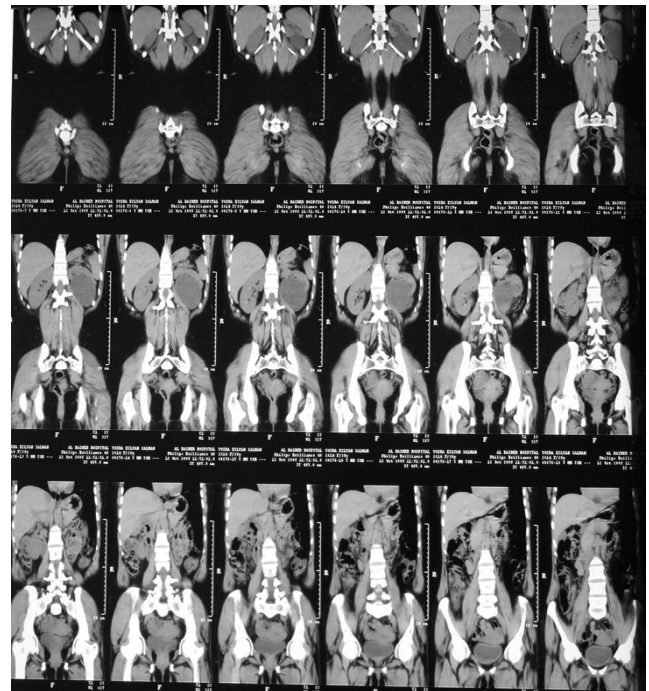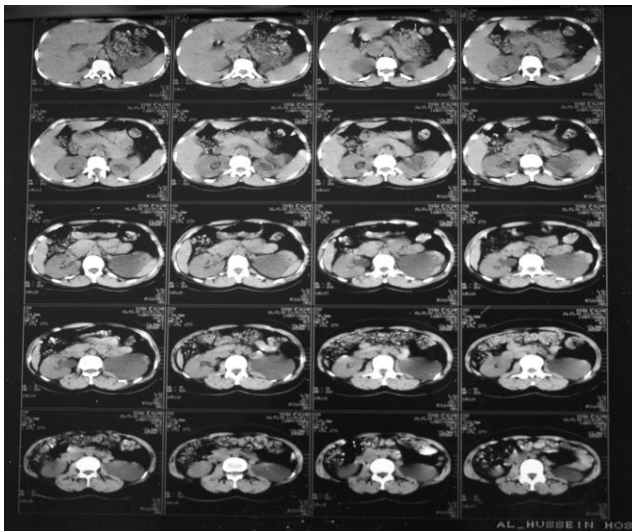
Fig.(8)-b

Renal isotopes scan showed hydronephrotic obstructed Lt kidney with impaired function, split renal function Rt kidney 69% Lt kidney 31%. Fig. (9)



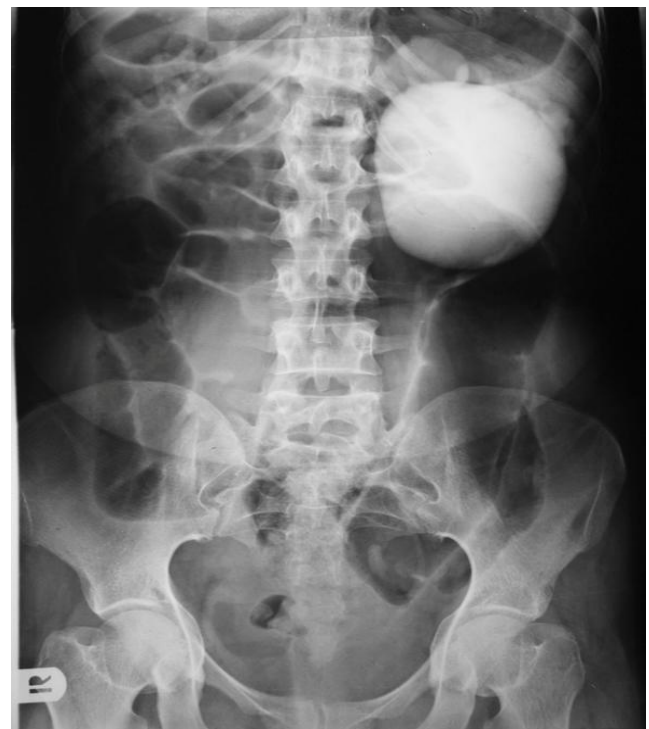**Fig.(9)**

Her CT scan: showed severely hydronephrotic changes and thin Lt Kidney is noted. Fig. (10)

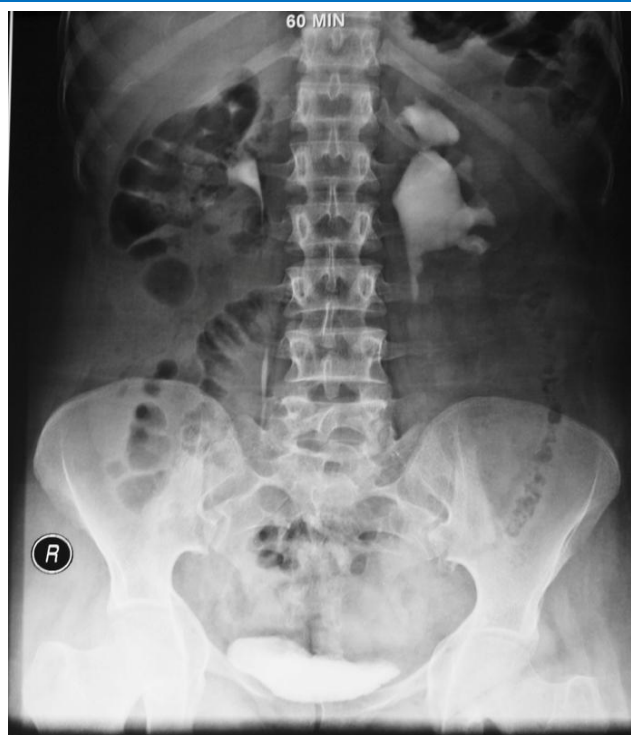
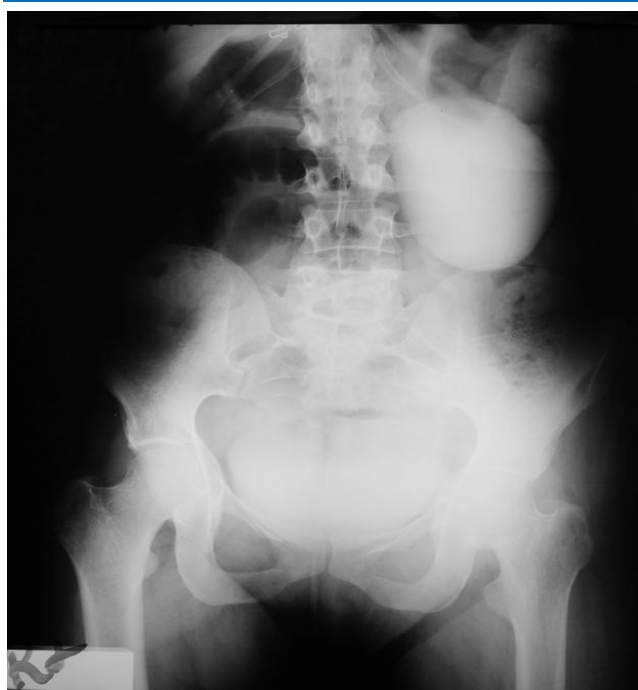
**Fig.(10)**

And her retrograde pyelography showed severe hydronephrosis in lower moiety of the Lt kidney and the upper moiety filled by dye in later stage pushed upward (huge Lt extrarenal pelvis malrotated obstructed Lt kidney, stenosis of Lt Pelvi-Ureteric Junction). Fig. (11)

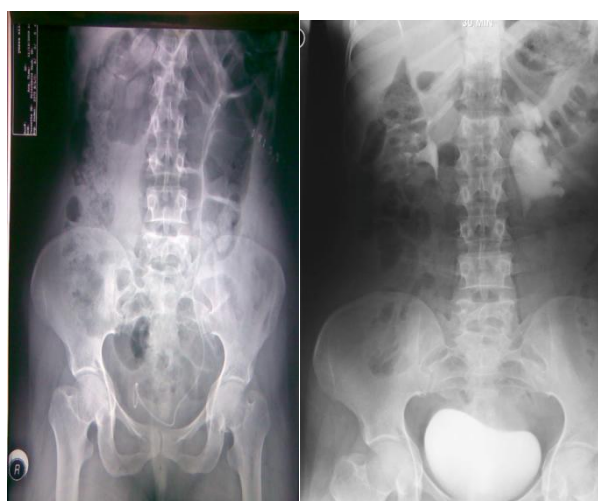
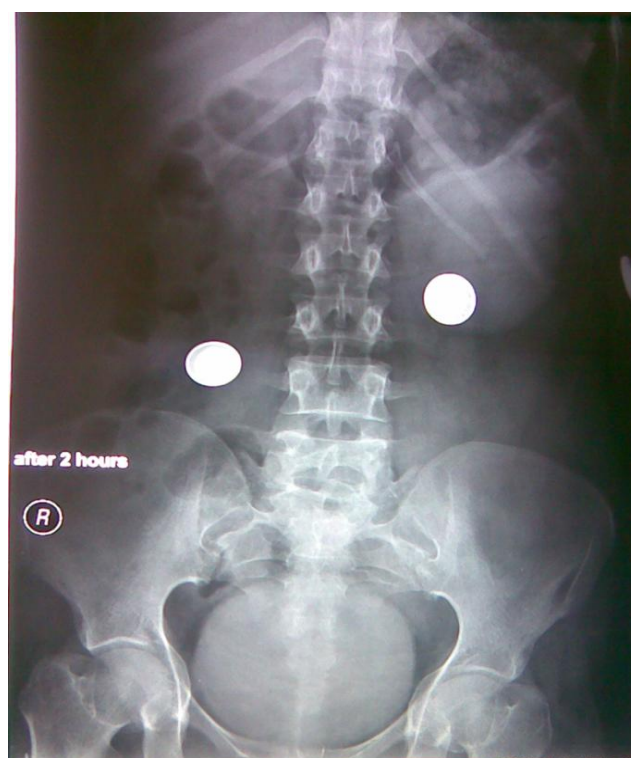


**Fig.(11)**



**Treatment:**

Double dismembered Anderson-Hynes pyeloplasty done on both moieties of the Lt Kidney: after excision of the stenotic part of the left ureter and redundant, severely dilated pelvis of lower moiety, first I anastomosed the upper segment of the left bifid ureter to the upper pole of pelvis(end to lateral anastomosis).Then I finished the second pyeloplasty as the ordinary method of Anderson -Hynes pyeloplasty. Postoperative period was uneventful. And in the postoperative period after 6 months, IVU performed and showed normal functioning of both kidneys Fig.(12)



**Fig.(12)**

**5. CONCLUSION**

Double pyeloplasty was performed, in the second case, to both moieties of bifid stenosed PUJ with severe hydronephrosis of the lower pole. **The**

**foregoing is recommended to be good** modality to resolve the obstruction of both moieties.

**REFERENCES**

- [1] Grobstein ;Activity in various embryonic and postembryonic sources for induction of kidney tubules Volume19,issue 1 January1969 pages41-51
- [2] Culp, O.S; Ureteral diverticulum : Classification of the literature and report of an authentic case, J. Urol,58:309-21,1947
- [3] Sariola ,H,Aniderheide,F,Bernhard, H, Henkee-Fahe,S,Dippold W and Ekblom,P(1988) Antibodies to cell surface ganglioside G D3 perturb inductive epithelial-mesenchymal interaction cell 54,235-245
- [4] McGraw, A.B, and O.S. Culp: Diverticulum of the ureter: report of another authentic case, J. Urol.(Baltimore) 67,262(1952)
- [5] Marshall, F.F and Melanghlin, M.G.: long blind ending ureteral duplication. J Urology,120:626-630,1978
- [6] Anomalies of the upper urinary tract. In Campbell Urology Vol 2, 5<sup>th</sup> edition. Editors. P.C. Walsh R,F GTTes, A.D Perlmutter and T.A. Stamey, WB Saunders Company Philadelphia, 1985, PP,1723-1724
- [7] Albers, DD, Geyer, J. R. and Barnes,S. E: Blind ending branch of bifid ureter: report of3 cases. J Urol., 99:160-164,1968